

## CURRENT AND FUTURE HORIZONS IN LARYNGEAL AND VOICE RESEARCH

PAUL H. WARD, MD  
BRUCE R. GERRATT, PhD

DAVID G. HANSON, MD  
GERALD S. BERKE, MD

LOS ANGELES, CALIFORNIA

Voice dysfunction is associated with neuromuscular impairment of laryngeal control and is often difficult to diagnose by indirect examination of the larynx. The newer techniques, currently used in the UCLA-Veterans Administration Medical Center Laboratories, provide some methods that aid in the diagnosis of voice impairment by providing documented objective data. Illustrative case reports of disorders of neuromuscular dysfunction of the larynx are presented and future research needs and direction are discussed.

KEY WORDS — electroglottography, laryngeal research, photoglottography, voice research.

The majority of voice disorders in all age groups are associated with pathologic abnormalities of the laryngeal structures. The diagnosis is often evident upon completion of a history and careful physical examination that demonstrates the anatomic abnormalities. Much more difficult is the diagnosis of voice impairment when there is no grossly evident anatomic abnormality.

In the absence of an obvious cause of a voice disorder, the history becomes even more important, for the patient can be observed and the voice heard simultaneously with the acquisition of data. While in this article emphasis is placed upon objective measurements, there remains no finer computer than that which rests upon our shoulders, when properly programmed and used. In many ways (voice quality, changes in pitch, breathlessness), the patients provide the diagnosis. Of importance also are the nonverbal clues: the patient's appearance, emotional state, and psychosocial, interpersonal, and occupational factors. The diagnosis of neuromuscular abnormalities affecting the larynx may be particularly difficult when only brief glimpses are obtained with the mirror or telescope.

In recent years, major advances have been made in our ability to document the appearance of the larynx. Motion pictures and, more recently, videotape photography of telescopic and fiberoptic examinations of the laryngeal and hypopharyngeal structures allow repeated and stop frame analyses of the dynamic events, with magnification and detail that increase diagnostic precision.<sup>1-5</sup> Commercially available systems provide immediate reproductions that can be shown to the patient and sent to the referring physician. Stroboscopy of the larynx has been used, discarded, and reused in many labora-

tories. It is now undergoing a resurgence, since new light source and stroboscopic units allow black and white or color videotaping and documentation of the stroboscopic image.<sup>6,7</sup> Unfortunately, a method of quantification of the stroboscopic image has yet to be worked out, but it does assist in differentiating between functional or structural bowing, and may show the cause of persistent dysphonia after laryngeal surgery by showing stiffening of the mucosal wave. Recent work in our laboratories now allows matching of the stroboscopic images with glottographic waveforms.

Among the objective measures currently in use in most voice laboratories are commercially available instruments that provide automated acoustic analysis of jitter, shimmer, and harmonic-to-noise ratio.<sup>8-10</sup> Aerodynamic measures, such as glottal airflow and subglottal air pressure, provide another perspective on voice production from which inferences on abnormal glottal configurations can be made.<sup>11</sup> Electromyographic recordings of laryngeal muscle activity provide useful information about the physiology of specific muscles during phonation.

Measurements that can be directly related to the pathophysiology of laryngeal behavior are highly desirable. Since phonatory dysfunction usually manifests itself in abnormal oscillatory movements, the measurement and analysis of the vibratory pattern of the vocal folds has the potential to provide detailed information on the pathophysiology of the vocal folds during phonation. Movement of the vocal folds can be observed by ultra-high speed filming (4,000 to 10,000 frames/s). Frame-by-frame analysis can yield measures such as glottal area and excursion of selected points on the visible surface of

From the Departments of Surgery/Head and Neck (Otolaryngology), UCLA School of Medicine and Wadsworth Veterans Administration Hospital, Los Angeles. Supported by Veterans Administration Medical Research Funds and National Institutes of Health grant NS 20707-05.

Presented at the meeting of the American Laryngological Association, Palm Beach, Florida, April 23-25, 1988.

REPRINTS — Paul H. Ward, MD, Division of Head and Neck Surgery (Otolaryngology), UCLA School of Medicine, 10833 LeConte Ave, Los Angeles, CA 90024-1624.

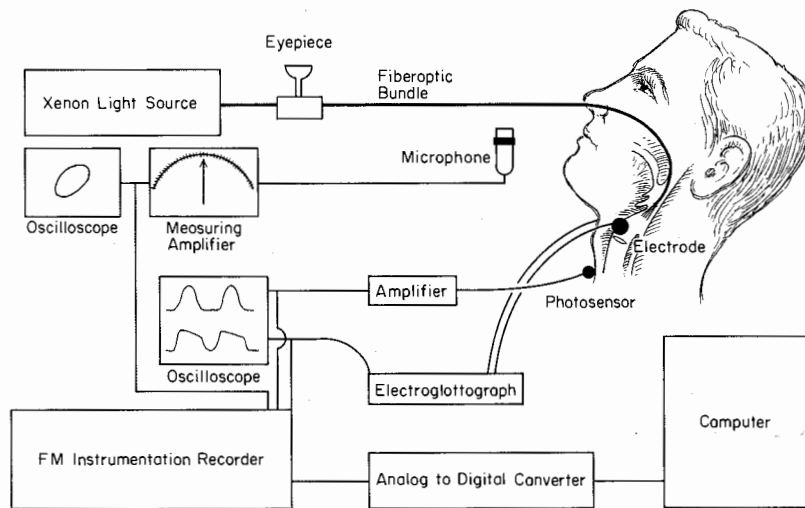


Fig 1. Diagram illustrating simultaneous recording of electroglottography and photoglottography and digitization apparatus.

the vocal folds. Such measures provide valuable information on the pathophysiology of individual patients. Although high speed filming does provide useful data, it is technically difficult to use with untrained subjects or patients, and is especially limited by the considerable time and expense of frame-by-frame data analysis. In fact, the difficulties of this method are so great that more than 40 years after first being used, it is estimated that not more than 5 minutes of ultra-high speed film of vocal fold vibration have been analyzed in detail.

The significant recent advance is the ability to assess the characteristics of phonatory function objectively at the level both of vocal fold vibrations and of the resulting acoustic signal. Two objective measures are photoglottography (PGG) and electroglottography (EGG).<sup>12</sup> The technology of digital recording and computer-assisted signal processing techniques has made feasible the documentation and analysis of such high speed events as vocal fold vibration and acoustic voice signals.<sup>13</sup> Glottographic techniques offer a rapid, relatively inexpensive alternative to high speed photography. Analysis of glottal waveforms, ie, waveforms that describe glottal movement during phonation, provide the potential for measurement of vocal fold activity with little discomfort to the patient. The application of voice and glottographic signal analysis in the evaluation of patient populations is providing data for objective assessment of voice disorders.<sup>14</sup>

The establishment of a voice disorders laboratory requires a broad-based multidisciplinary approach to phonatory physiology and pathophysiology. A well-equipped laboratory provides the investigators with the capacity to document fiberoptic, telescopic, and stroboscopic laryngeal examination, high quality reproductions of acoustic voice signals, glottal airflow and pressure measurements, and glottographic assessment of vibration.<sup>15</sup> Computing facility capability allows simultaneous digital recording of multiple signals for subsequent auto-

ated or interactive analysis of data. A diagram of the recording and digitization apparatus is illustrated in Fig 1.

The vibratory movements of the vocal folds during voice production occur faster than the eye can follow, and objective measurements of these vibratory movements offer advantages over purely visual examination techniques.<sup>15</sup> New data are accumulating to confirm the objective measurements of vocal fold vibratory function with EGG<sup>16</sup> and PGG.<sup>17</sup> Electroglottography provides measurements of the changes in electrical impedance across the larynx during vocal fold opening and closing. The dynamic impedance between the two skin electrodes that changes as the vocal folds spread apart and then approximate each other is recorded by EGG. A generally accepted interpretation of the events seen in a normal EGG pattern is seen in Fig 2A.

Comparison of stroboscopic images with EGG confirms the view that EGG signals reflect the variations in vocal fold contact.<sup>18</sup> Photoglottography measures the light transmission between the vocal cords (the glottic chink) during phonation. A light source is placed in the oral cavity, while a photosensor placed on the neck at a level below the vocal cords measures the amount of light transmitted through the cords during phonation. Photoglottography measures the light transmission between the vocal cords (the glottic chink) during phonation. An interpretation of events seen in a normal PGG is demonstrated in Fig 2B.

Comparisons of high speed photography with that of the intensity of light transmitted during PGG is a good approximation of cross-sectional area of the glottis during phonation.<sup>19-21</sup> Photoglottography and EGG are complementary measures; one describes the glottic opening while the other provides information on the glottic closure.<sup>21</sup> The EGG and PGG waveforms also can be used to calculate two other possibly useful measurements: the speed

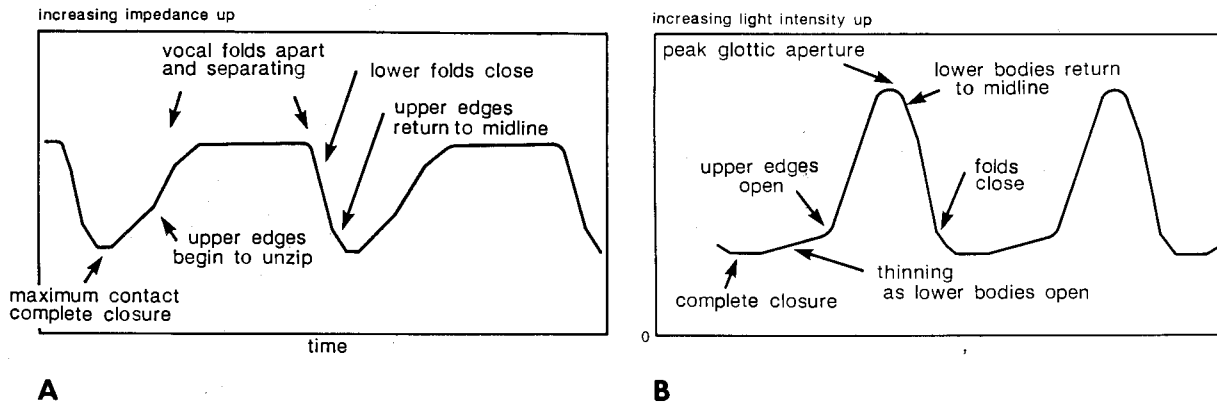


Fig 2. Events identified in normal glottography signals. A) Electroglottography (impedance/time). Idealized waveform modified from Rothenberg. (Rothenberg M. Some relations between glottal air flow and vocal fold contact area. In: Ludlow C, Har M, eds. Proceedings of the Conference on the Assessment of Vocal Pathology, Report 11. Rockville, Md: American Speech and Hearing Association, 1981:88-95.) B) Photoglottography (glottic area curve/time).

quotient and the open quotient. The open quotient represents the fraction of time the vocal folds are open during the glottic cycle, and the speed quotient the time they are opening divided by the time they are closing.

#### METHOD

Our method for examining a patient with phonatory disorders has been published previously.<sup>12</sup> We have converted from 16-mm motion pictures to  $\frac{3}{4}$ -inch videotape obtained with a miniature video-camera. The control data from ten normal male volunteers in good physical condition and screened for absence of voice abnormalities has been presented previously.<sup>22,23</sup> All subjects were recorded in a double-walled, sound treated (Industrial Acoustics Corp) room. The subjects vocalized a sustained /i/ while videolaryngoscopic documentation of the gross laryngeal movement and anatomy and PGG and EGG signals were recorded. During phonation of this vowel, the epiglottis is in a forward position, thus minimizing obstruction of supraglottic light for PGG.

The PGG measurement system consists of a Centronic, single element photovoltaic detector with an active area of 50 mm<sup>2</sup>, followed by a preamplifier with a bandwidth of around 5 kHz. The preamplifier and photodetector are encapsulated in plastic and electromagnetically shielded. The photodetector is placed on the skin of the neck overlying the cricothyroid membrane. The larynx is illuminated by projection of light through an Olympus flexible fiberoptic telescope inserted through a nostril and positioned so that the glottis fills 50% of the viewing field; a 350-W xenon light serves as the illumination source.

The EGG signals were recorded using a Synchron voice research electroglottograph attached to the subject by an elastic collar. The two surface electrodes were located on either side of the thyroid alae, and a ground electrode was placed on the side

of the neck. At comfortable pitch and loudness levels, the PGG and EGG signals are recorded simultaneously during steady state phonation of the vowel /i/. Both control and patient subjects attempted to match frequency and intensity targets. The glottographic signals were recorded for later analysis on a four-channel FM recorder (Tandberg).

The recorded signals were low-pass filtered at 3 kHz and synchronously digitized at a sample rate of 20,000 points per second. The multipurpose signal analysis program is used to mark several points for each glottic cycle. Gerratt et al<sup>22</sup> described the point of opening of the glottis to airflow. The point of peak opening is determined from the zero crossing of the velocity of the PGG signal. The amplitude of this peak is measured. Baseline signal is determined by the PGG amplitude at the point that the EGG signal indicates minimum impedance (maximum contact across the glottis). The point of closing is marked at the peak deceleration of the PGG signal, which corresponds most closely with the peak closing velocity of the EGG signal.

Fifty cycles of representative phonation are used to acquire the various measurements. The time-related measurements include the period of each cycle, the closed phase, the open phase, the period during the open phase in which the glottic area is increasing, and the period during which the open phase of the glottis is decreasing.

High quality acoustic recordings are made during sustained vowel production in each subject. Vocal tract resistance is calculated from airflow and from estimated subglottal pressure signals. Acoustic, perceptual flow, and pressure data are in the process of analysis for future reports. An example of the normal, simultaneously recorded waveforms of EGG and PGG is presented in Fig 3A. These normal waveforms can be compared visually with those recorded from patients with various central and peripheral pareses, paralysees, and central de-

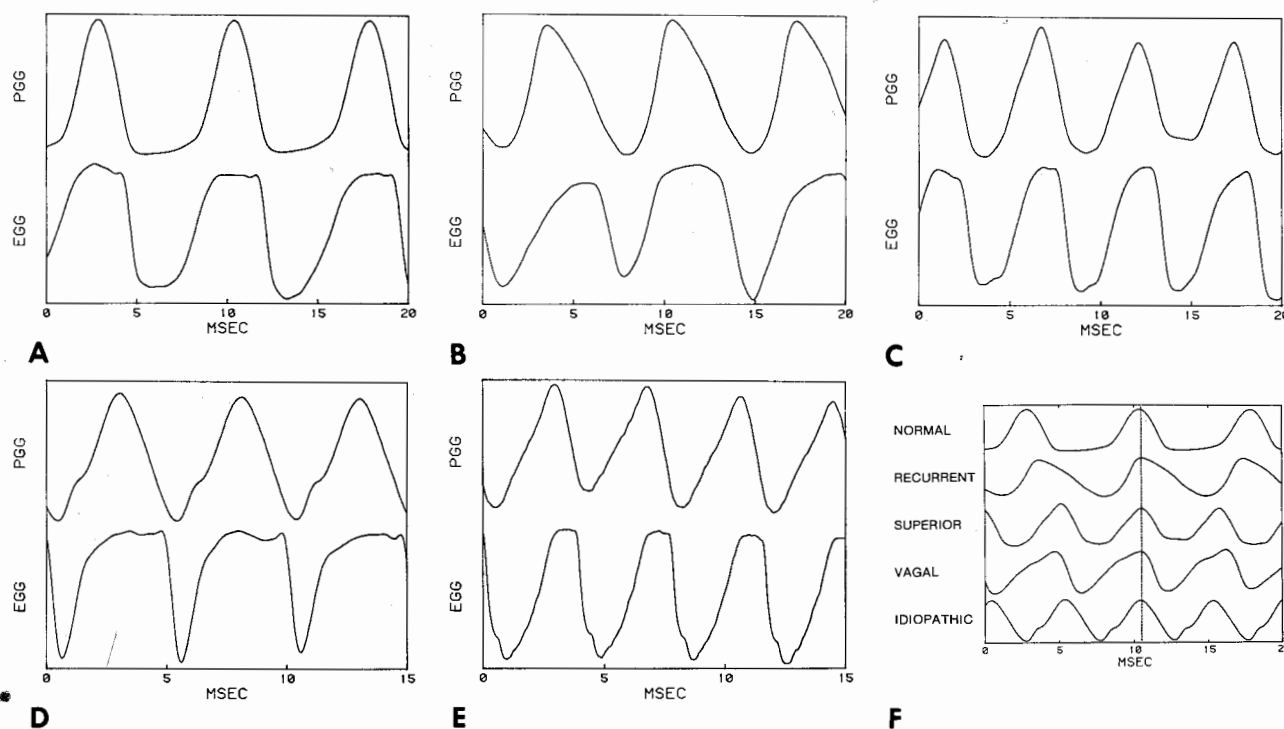


Fig 3. Typical simultaneously recorded electroglottography (EGG) and photoglottography (PGG). A) Normal. B) Recurrent laryngeal nerve section. C) Superior laryngeal nerve paralysis. D) Idiopathic paralysis. E) High vagal nerve section. F) Composite for comparison of PGG patterns.

generative processes (eg, Parkinson's disease, essential tremor).

The EGG and PGG signals recorded in a patient with the recurrent laryngeal nerve sectioned show an open period for most of the glottic cycle (Fig 3B). The duration of the opening phase is less than half the duration of the closing phase. The EGG signal reaches peak impedance at approximately the same time that the projected glottal area is maximum. This differs from the normal pattern (Fig 3A), in which the plateau of the EGG impedance occurs prior to the peak glottal aperture. The EGG signal waveform in patients with recurrent nerve section is less flat than is the normal pattern and occurs early in the duty cycle compared to normal signals.

In isolated superior laryngeal nerve paralysis, there are visibly determinable differences from recurrent nerve paralysis. Figure 3C shows that the baseline glottic closure varies from cycle to cycle. The duration of the opening is longer than the closing cycle. Comparing these to normal signals and to recurrent nerve paralysis, there is greater irregularity from cycle to cycle, often in a recurring pattern over several cycles. Patients with superior laryngeal nerve paralysis have EGG signals that show peak incidence (reflecting maximum separation of the vocal folds) occurring relatively late in the cycle. The plateau of the EGG comprises less duration of the cycle than in the normal subjects and patients with recurrent laryngeal nerve paralysis.

The PGG and EGG pattern of patients with idio-

pathic paralysis is shown in Fig 3D. These can be compared and contrasted with those seen in patients with recurrent laryngeal paralysis. The glottis is open for most of the cycle. Patients with idiopathic paralysis have prolongation of the opening phase in comparison to the closing phase when compared with the pattern seen in recurrent laryngeal nerve paralysis. There are also changes in the velocity of the opening slope of the PGG. The EGG signals from the idiopathic paralysis patients show that maximal impedance, ie, least contact of the folds, occurred in different patients at variable relationships with the peak of PGG.

The PGG and EGG signals from a patient with high vagal nerve section are seen in Fig 3E. There is no closed period in the glottic cycle, as noted in the variation in the baseline. The duration of opening seen in the PGG is prolonged in relation to closing, with a brief change in the velocity in the opening slope. Lack of vocal fold approximation is reflected in the EGG by a low signal-to-noise ratio.

It is obvious from examination of the signals recorded in patients with carefully selected laryngeal nerve and idiopathic paralyse that specific variations in vibratory pattern are detectable. The various PGG patterns characteristic of each type of paralysis are shown for comparison in Fig 3F.

#### CASE REPORTS

Three cases are presented to illustrate currently available techniques of objective documentation

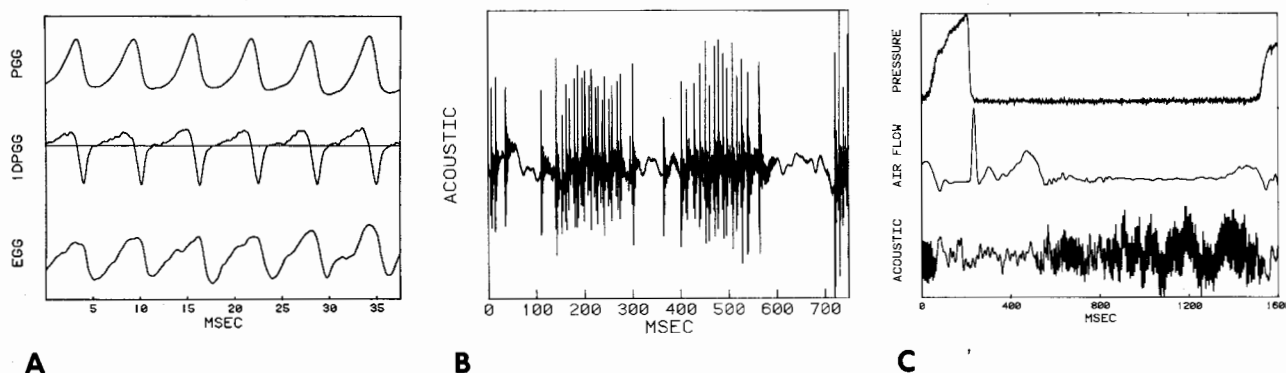


Fig 4. Recordings from patients in case reports. A) (Case 1) Glottographic patterns showing findings typical of Parkinson's disease. PGG — photoglottography, 1DPGG — derived PGG, EGG — electroglottography. B) (Case 2) Acoustic signal recording in patient with myoclonic tremors. C) (Case 3) Pressure, airflow, and acoustic signal recordings in patient with essential tremor.

that are applied to evaluate difficult voice problems and assist in diagnosis.

**Case 1.** A 67-year-old man who was a heavy voice user presented with a complaint of progressive fatigue and hoarseness. His voice was weak and became more breathy as the day progressed. He had seen several other otolaryngologists concerning his voice abnormality. On minor examination, he had been told that his larynx was normal and he had been referred for speech therapy, which provided minimal beneficial effect. Videolaryngoscopy showed a normal range of laryngeal movement. On close examination during phonation, it was apparent that the vocal processes approximated firmly, but the vocal folds appeared rigid and bowed.

Simultaneously recorded PGG and EGG signals in this patient are seen in Fig 4A. The PGG signal, reflecting the cross-sectional glottal area, indicates that there is an ill-defined baseline during the closed period. There is also asymmetry in the open period, which is better reflected in the opening and closing velocity seen in the derived tracing (1DPGG). The EGG signal, reflecting the vocal fold contact area, is noisy (often with poor vocal fold approximation during the closed phase) and shows maximal impedance (associated with maximum separation of the vocal folds) occurring rather late in relation to the peak glottic area seen in the PGG. These patterns of glottographic signals are typical of those seen in patients who have Parkinson's disease involving the laryngeal muscles.<sup>23,24</sup>

**Comment.** On the basis of this evaluation, it was recommended that the patient have a neurologic consultation. The patient was told that his voice dysfunction was the result of a neuromuscular control problem. Voice rehabilitation oriented toward the observed disorder was much more effective in helping the patient to cope with his laryngeal dysfunction than had been prior therapy. Two years later, on the basis of subsequent development of other symptoms and signs, the diagnosis of Parkinson's disease was confirmed.

**Case 2.** A 64-year-old woman was referred for evaluation of spastic dysphonia. The patient, a trained professional singer, had noted gradual onset of extreme difficulty in intensity and pitch. Examination with mirror and the 90° telescope was difficult, but showed hyperadduction of the vocal folds in phonation. The experienced examiner was not successful in observing respiratory movements clearly. A flexible fiberoptic telescope therefore was introduced. Monitoring the patient's hypopharynx showed a regular rhythmic jerking of the larynx at about 2 Hz.

Figure 4B demonstrates the patient's voice signal for a period of 2 seconds during attempted prolonged phonation of the vowel /a/. The jerking movement, also present during quiet respiration, was asymmetrical, primarily to the left side. The magnitude of the myoclonic movement appeared to change with the respiratory cycle, being more prominent at the end of inspiration. During phonation, the attempt to superimpose voicing on the myoclonic movements of the larynx resulted in the observed voice disorder.

**Comment.** Myoclonus of muscles supplied by the vagal nerve is thought to result from a supranuclear brain stem lesion. Subsequent neurologic evaluation, including a good quality magnetic resonance imaging scan, failed to localize a specific lesion in this patient. In our experience, a specific lesion usually is not identified in patients who demonstrate palatolaryngopharyngeal myoclonus.

**Case 3.** An 80-year-old woman complained of progressive, gradual deterioration of her voice over the past 7 to 8 years. Her voice was weak and crackling, but at times it sounded spastic in nature and she would have to use force to produce words. The voice problem was intermittent, with good and bad days. At times, she felt that the air "just shut off." She had no previous voice therapy. Objective measurements are demonstrated in pressure, airflow, and acoustic signals recorded in Fig 4C, in which the patient is making the utterance /pa/.

Because of the essential tremor, there is an abnormally long, 400-ms latency present between the onset of the acoustic sound, manifested by the escape of airflow before the normal /a/ is heard.

*Comment.* Additional objective measurement in this case helped us to understand the dynamic interactions between the tremor and incoordination with breathing.

#### DISCUSSION

Presently available techniques for documentation and analysis of vocal fold vibrations are providing us with valuable diagnostic information concerning the glottographic patterns of various neuromuscular diseases. The various types of laryngeal paralysis can now be recognized by photographic, video, and glottographic measurements.<sup>23</sup> Characteristic patterns are being used to detect Parkinson's disease even before other neurologic signs and symptoms appear (case 1, Fig 4A). Recognition and separation of the glottographic patterns of essential tremor, myasthenia laryngis, and spastic dysphonia as well as many other neuromuscular disorders of the larynx are now feasible.<sup>15,25</sup>

To better understand the pathophysiologic significance of these observations, we examined an *in vivo* canine model of vocal fold vibration reported by Berke et al<sup>26</sup> and Moore et al.<sup>7</sup> Lesions of recurrent laryngeal nerve, superior laryngeal nerve, and a combination of the two were produced in the canine model. The PGG and EGG waveform patterns recorded in the canine models were similar to those documented for normal human subjects as well as for human patient data for respective types of paralysis. Simultaneous stroboscopy, triggered from a sharp negative spike in the velocity of the EGG signal, allowed observation of the vibratory movements that were associated with the glottographic waveforms.

In modeled normal phonation, it appears that the velocity of the opening slope of the PGG was determined by movements of the upper edges of the vocal folds. Closing of the glottal aperture reflected movements of the lower bodies of the folds. The increasing impedance of the EGG signal preceded the opening movements of the projected glottic aperture reflected in the PGG signal because the folds opened from below and the lower bodies of the cords reached maximal separation before the upper edges unzipped.

In modeled recurrent nerve paralysis, the flaccid cord did not vibrate in the normal two-mass mode, but rather was pushed laterally as one mass by the subglottal pressure. This was associated with relatively rapid opening of the glottis toward the side of the flaccid fold. The midline of the glottal area shifted toward the flaccid fold. Closure occurred with the upper edge of the normally innervated fold

crossing the midline. This resulted in a picture that was very similar to data reported from the few high speed cinelaryngoscopic studies of recurrent nerve paralysis in humans.<sup>27</sup> The pattern of PGG and EGG signals recorded in the model was similar to that seen for the recurrent laryngeal nerve paralysis patients. The glottographic signals recorded from these patients appear to reflect a pathologic vibratory pattern in which the flaccid vocal fold offers little resistance to subglottal pressure. When one fold is paralyzed, the upper edge of the flaccid fold moves laterally relatively early in the cycle, and therefore the opening slope of the PGG reflects primarily the movements of the flaccid cord. The flaccid cord also appears to be delayed in return to the midline, and glottic closure does not occur until the upper edge of the normal vocal fold crosses the midline to approximate the paretic fold. This results in a relatively decreased velocity of the closing slope of the PGG signal. The EGG signal also reflects the rapid separation of the folds early in the sequence of glottal opening.

In the canine model of superior laryngeal nerve paralysis, the upper edges of the folds vibrated 90° out of phase with the normal pattern. There was a clear shift of the posterior commissure toward the side of paralysis with the onset of phonation. On viewing from below, the vocal fold on the side of cricothyroid paralysis first moved laterally. As the subglottic air pulse reached the upper edges of the folds, the midline of the glottic aperture moved markedly toward the side of paralysis. The mucosal wave of both vocal folds then rolled toward the side of intact cricothyroid function. The picture from above showed the epithelial coverings of both folds rolling first to one side, then to the other, with each glottal pulse. The visible glottic aperture viewed from below the folds during stroboscopy traveled from the paretic side to the more tensed side as opening progressed toward the upper edges. As seen from below, it was apparent that the cross-sectional area of the glottic aperture, represented in the PGG signal, resulted from complex interactions of the movements of the lower and upper portions of two folds that, although vibrating at the same frequency, were vibrating out of normal phase with each other. The discontinuity in velocity of the opening slope of the PGG signals and the irregularity of glottographic signal patterns reflect these complex vibratory interactions. Such complex interactions were predicted by Isshiki et al<sup>28</sup> in models of asymmetric vocal fold tension.

With modeled combined paralysis of recurrent laryngeal and superior laryngeal nerves, a combination of the effects of flaccid paralysis with asymmetry of longitudinal tension was observed in the vibratory pattern. The body of the intact, more stretched fold, viewed from below, appeared to vibrate very little, remaining near the midline. As viewed from above, the opening of the upper edges

of the vocal folds was distinctly prolonged. Opening progressed from posterior to anterior. Lateral and medial movements of the upper edge of the flaccid fold lagged behind the movements of the more stretched fold. When the lateral excursion of the epithelium of the upper mucosal cover was maximal, the lower body of the intact vocal fold already had returned to midline. Closure of the glottic aperture then occurred very rapidly as the lower body of the intact vocal fold approximated the flaccid fold. The pattern of the PGG waveform seen for vagal nerve paralysis reflected the effects on cross-sectional glottal aperture of prolonged unzipping of the upper edges and phase lag of the lateral and medial movement of the fold on the side of paresis. The PGG and EGG signal patterns and their relationship in the canine model of vagal nerve paralysis approximated the appearance of our vagal nerve paralysis patient's data seen in Fig 3E. This pattern of the EGG signal in relation to the PGG signal appeared to be associated with lack of firm approximation of the bodies of the folds so that the EGG signal reflected primarily the degree of contact of the upper edges. Because of the prolonged opening of the upper fold edges, maximal separation of the epithelial edges occurred relatively late in the cycle, at a time when medial movement of the body of the intact fold already was reducing the cross-sectional glottal aperture. Soon thereafter, contact of the lower bodies of the folds occurred. Thus the plateau of the EGG occurred late in the duty cycle and was of relatively short duration.

The differing patterns seen in the PGG and EGG signals from patients with specific lesions of the laryngeal nerves are consistent with effects predicted by animal model studies. The data from the patient group with idiopathic paralysis are most consistent with the conclusion that these individuals had a le-

sion that affected motor innervation to both the intrinsic laryngeal muscles and the cricothyroid muscles on the same side of the larynx. The glottographic patterns of vibration were most similar to those seen in patients with vagal nerve section. Previous reports have suggested that the lesion in idiopathic paralysis of the larynx is usually a high vagal or a central lesion.<sup>3</sup>

What can be anticipated for the future in voice research? What should be the future priorities? Already, multiple quantitative measurements determined from glottographic signals are being made, and additional data will be published.<sup>23</sup> These include the open quotient, speed quotient, and shift quotient.

The speed quotient appears to be sensitive to gross variations in neuromuscular tension of the vocal folds in specific neuromuscular disorders. With the shift quotient it is now possible to interlock the PGG, EGG, and videostroboscopy wave motion.<sup>29</sup> The objective quantification consistently shows a close relationship with the glottographic waveforms of the various neuromuscular disorders, thus allowing mathematic analysis. These quantitative measures allow pretherapy and posttherapy measurements, thereby determining changes effected by the treatment.

The future should allow us to quantify both in animal models and in patients the effectiveness or lack thereof of hormonal, pharmacologic, rehabilitative, and surgical therapy. Cooperative team investigative efforts should include an otolaryngologist, an endocrinologist, a neurologist, a physiologist, and a neurophysiologist working with a voice scientist in order to gain a greater understanding of the causes and correction of voice disorders in health and disease.

#### REFERENCES

1. Ward PH, Berci G, Calcaterra TC. Advances in endoscopic examination of the respiratory system. *Trans Am Broncho-Esophagol Soc* 1974;143-9.
2. Tobin HA. Office fiberoptic laryngeal photography. *Otolaryngol Head Neck Surg* 1980;88:172-3.
3. Ward PH, Berci G. Observations on so-called idiopathic vocal cord paralysis. *Ann Otol Rhinol Laryngol* 1982;91:558-63.
4. Yanagisawa E. Office telescopic photography of the larynx. *Ann Otol Rhinol Laryngol* 1982;91:354-8.
5. Yanagisawa E, Owens TW, Strothers G, Honda K. Videolaryngoscopy. A comparison of fiberoptic and telescopic documentation. *Trans Am Laryngol Assoc* 1983;104:34-40.
6. Kitzing P. Stroboscopy — a pertinent laryngological examination. *J Otolaryngol* 1985;14:151-7.
7. Moore DN, Berke GS, Hanson DG, Ward PH. Videostroboscopy of the canine larynx: the effects of asymmetrical laryngeal tension. *Laryngoscope* 1987;97:543-53.
8. Koike Y. Application of some acoustic measures for the evaluation of laryngeal dysfunction. *Stud Phonologica* 1973;7:17-23.
9. Horii Y. Fundamental frequency perturbation observed in sustained phonation. *J Speech Hear Res* 1979;22:5-9.
10. Koike Y. Vowel amplitude modulations in patients with laryngeal diseases. *J Acoust Soc Am* 1969;45:839-44.
11. Netsell R, Shaughnessy AL, Lotz WK. Laryngeal aerodynamics for selected vocal pathologies. *Abstr Assoc Res Otolaryngol* 1983:80.
12. Hanson DG, Gerratt BR, Ward PH. Glottographic measurement of vocal dysfunction. A preliminary report. *Ann Otol Rhinol Laryngol* 1983;92:413-20.
13. Daniloff R. Laryngeal function in phonation and respiration. *ASHA* 1988;30:60-1.
14. Kitzing P. Glottography, the electrophysical investigation of phonatory biomechanics. *Acta Otorhinolaryngol Belg* 1986;40:863-78.
15. Hanson D, Ward PH, Gerratt BR, Berci G, Berke G. Diagnosis of neuromuscular disorders. In: Goldstein J. *Ceriatric otolaryngology*. Philadelphia: BC Decker, 1988 (in press).
16. Fabre P. Un procede électrique percutané d'inscription de l'accolement glottique au cours de phonation: glottographie à de haute fréquence. *Bull Acad Natl Med (Paris)* 1957;121:66-9.
17. Sonesson B. A method for studying the vibratory move-

ments of the vocal cords. *J Laryngol Otol* 1959;73:732-7.

18. Fourcin AJ. Laryngographic examination of vocal fold vibrations. In: Wyke B, ed. *Ventilatory and phonatory control mechanisms*. Oxford, United Kingdom: Oxford University Press, 1975:315-33.

19. Zemlin WR. A comparison of high speed cinematography and a trans-illumination-photoconductive method in the study of the glottis during voice production [Thesis]. Minneapolis: University of Minnesota, 1959.

20. Harden RJ. Comparison of glottal area changes as measured from ultra-high speed photographs and photoelectric glottographs. *J Speech Hear Res* 1975;18:728-38.

21. Baer T, Lofqvist A, McGarr NS. Laryngeal vibrations: a comparison between high-speed filming and glottographic techniques. *J Acoust Soc Am* 1983;73:1304-7.

22. Gerratt BR, Hanson DG, Berke G. Glottographic measures of laryngeal function in individuals with abnormal motor control. In: Harris K, Sasaki C, Baer T, eds. *Vocal fold physiology: laryngeal function in phonation and respiration*. San Diego: College Hill Press, 1986:521-32.

23. Hanson DG, Gerratt BR, Karin RR, Berke GS. Glotto-

graphic measures of vocal fold vibration: an examination of laryngeal paralysis. *Laryngoscope* 1988;98:541-9.

24. Timcke R, von Leden H, Moore P. Laryngeal vibrations: measurements of the glottic wave. Part 1. The normal vibratory cycle. *Arch Otolaryngol* 1958;68:1-19.

25. Hanson DG, Gerratt BR, Ward PH. Cinegraphic observations of laryngeal function in Parkinson's disease. *Laryngoscope* 1984;94:348-53.

26. Berke GS, Moore DM, Hantke DR, Hanson DG, Gerratt BR, Burstein F. Laryngeal modeling: theoretical, in vitro, in vivo. *Laryngoscope* 1987;97:871-81.

27. Von Leden H, Moore P. Vibratory pattern of the vocal cords in unilateral laryngeal paralysis. *Acta Otolaryngol (Stockh)* 1961;53:493-506.

28. Isshiki N, Tanabe M, Ishizaka K, Broad D. Clinical significance of asymmetrical vocal cord tension. *Ann Otol Rhinol Laryngol* 1977;86:58-66.

29. Trapp TK, Berke G, Bell TS, Hanson DG, Ward PH. Effect of vocal fold augmentation on laryngeal vibration in simulated recurrent laryngeal nerve paralysis: a study of Teflon and Phonogel. *Ann Otol Rhinol Laryngol* 1989;98 (in press).