

Treatment of Parkinson Hypophonia With Percutaneous Collagen Augmentation

Gerald S. Berke, MD; Bruce Gerratt, PhD; Jody Kreiman, PhD; Katherine Jackson, RN

Objectives: It has been estimated that more than 70% of patients with Parkinson disease experience voice and speech disorders characterized by weak and breathy phonation, and dysarthria. This study reports on the efficacy of treating Parkinson patients who have glottal insufficiency. **Study Design and Methods:** Thirty-five patients underwent collagen augmentation of the vocal folds for hypophonia associated with Parkinson disease, using a new technique of percutaneous injection with fiberoptic guidance. Patient response to the collagen augmentation was determined by telephone survey. **Results and Conclusions:** The procedure required minimal patient participation and was safely performed on all the patients who were studied. Results of the survey indicated that 75% of patient responses demonstrated satisfaction with the technique, compared with 16% of patient ratings reflecting dissatisfaction. These results were moderately correlated with the duration of improvement of the dysphonia. Results of this preliminary evaluation demonstrate that voice deficits in Parkinson disease are amenable to vocal fold augmentation. Because this procedure requires minimal patient participation and can be safely performed in an office setting, it may also be useful in other severely debilitating neuromotor diseases that result in glottal insufficiency and hypophonia. **Key Words:** Parkinson disease, dysphonia, glottal incompetence, larynx, collagen injection.

Laryngoscope, 109:1295-1299, 1999

INTRODUCTION

Parkinson disease affects over more than one and a half million Americans. More than 70% of patients with this disorder experience problems with speech and voice and 30% of patients describe these abnormalities as the most debilitating deficit related to their Parkinson disease.¹ Patients with Parkinson disease often have decreased duration of vocalic segments, decreased formant transitions, and increased voice onset time compared with

normal.² Darley et al.³ reported perceived reduced variability in pitch and loudness and harsh and breathy vocal quality as the most deviant voice dimensions among a group of subjects with Parkinson disease. Hanson et al.⁴ examined the larynges of Parkinson patients and documented the typical bowed appearance of the vocal folds that results in glottal incompetence and weak voice. They assumed this glottal deviation resulted from muscle rigidity typically associated with Parkinson disease, and more readily observed in the limb musculature. More recently, Leopold et al.⁵ reported that the intrinsic laryngeal muscles are more often "defective" during phonation. They concluded that laryngeal dysmotility may be related to defective descending basal ganglionic control of phonation.

There are a few treatment approaches currently used to reduce the debilitating effects of Parkinson disease. Unfortunately, fetal transplantation of dopaminergic cells, pallidotomy, and deprenyl therapy have not consistently improved voice and speech production.⁶⁻⁸ However, Ramig et al.⁹ have successfully applied a behavioral approach based on increased vocal effort to increase loudness in Parkinson patients. They suggested that a combination of increased vocal fold adduction and subglottal pressure is key in generating posttreatment increases in vocal intensity.¹⁰

Despite the fact that glottal incompetence often underlies Parkinson patients' voice complaints, surgical methods for improving vocal fold adduction have not been reported. Four main considerations make these patients poor candidates for phonosurgery. First, Parkinson patients have good vocal fold mobility, usually demonstrating normal vocal process excursion for phonation and inspiration.¹¹ Traditional methods of vocal fold augmentation typically are used to improve position in an immobilized vocal fold, and thus most surgeons would not consider Parkinson patients as candidates. Second, because Parkinson disease is a progressive disorder, any treatment should be easily revised to accommodate deteriorating neuromotor function. However, traditional surgeries such as laryngoplasty (type I thyroplasty and arytenoid adduction) and injection of alloplastic and autogenous materials produce permanent or long-lasting effects. Third, modalities that require patient cooperation and participation, such as transoral injection techniques or even percutaneous augmentation using local anesthetics, hydraulic

From the Division of Head/Neck Surgery, UCLA School of Medicine, Los Angeles, California.

Editor's Note: This Manuscript was accepted for publication May 4, 1999.

Send Reprint Requests to Gerald S. Berke, MD, Division of Head/Neck Surgery, UCLA School of Medicine, CHS 61-132, Los Angeles, CA 90095, U.S.A.

injectors, and large-bore 18-gauge needles, will likely be problematic in a significant portion of the Parkinson patient population. Finally, general anesthesia is usually contraindicated in these neurodegenerative disorders.

Given these considerations, an ideal treatment modality for these patients would be minimally invasive, require only a low level of patient cooperation, function for only a moderate period of time to allow modification by repeated application, not interfere with arytenoid movement, and allow precise adjustment of vocal fold configuration as required. This study describes a vocal fold augmentation technique using percutaneous collagen injection under fiberoptic guidance,¹² that attempts to fulfill these five criteria. Bovine collagen has been used for more than 15 years to treat laryngeal insufficiency^{13,14} and bowed vocal folds.¹⁵ It can be injected precisely in planes near the vocal ligament, through small-gauge needles.¹⁶ It does not interfere with traveling wave motion, providing an almost painless approach through the thyroid lamina or cricothyroid membrane. After injection, collagen may exist in the larynx for more than 1 year.¹⁷ Glutaraldehyde crosslink collagen has additional advantages, including greater persistence, less shrinkage with a correspondingly reduced need for reinjection, and less than 1% incidence of hypersensitivity.¹⁸

MATERIALS AND METHODS

Patient Selection and Evaluation

Thirty-five patients who have received collagen injections for treatment of dysphonia subsequent to Parkinson disease were included in this study. All patients had the neurologic diagnosis of idiopathic Parkinson disease and all were either receiving current anti-Parkinsonian medication or had undergone fetal tissue transplantation or pallidotomy. All patients were experiencing significant speech and/or voice abnormalities, as described above.

The patients underwent a comprehensive preinjection voice evaluation, including evaluation by a speech-language pathologist and instrumental evaluation. The patients included in this study exhibited incomplete glottal closure, identified stroboscopically as persistent glottic aperture during vibration encompassing at least the middle one third of the membranous glottis. Further, the estimated laryngeal airway resistance (as described by Smitheran and Hixon¹⁹) of these patients was within or below one SD of the mean resistance reported for normal speakers at comfortable loudness.²⁰ Patients with speech disturbances related to Parkinson disease but with normal glottal closure were excluded from this study. Patients were initially evaluated for hypersensitivity to collagen using one or two test doses of bovine collagen before injection.

Injection Technique

The injection technique is similar to a technique described previously for injection of botulinum toxin.¹³ Topical anesthesia using aerosolized phenylephrine 1% and 4% lidocaine was applied to the nasopharynx, and additional aerosolized lidocaine or benzocaine were applied to the oral cavity and hypopharynx to reduce nasal irritation and gagging during the insertion of the nasopharyngoscope. No local anesthetic injections were used at the collagen injection site.

An Olympus (Melville, NY) P3 nasopharyngoscope connected to a Storz (Culver City, CA) Tricam digital camera was utilized for laryngeal imaging. The optional red/green/blue output

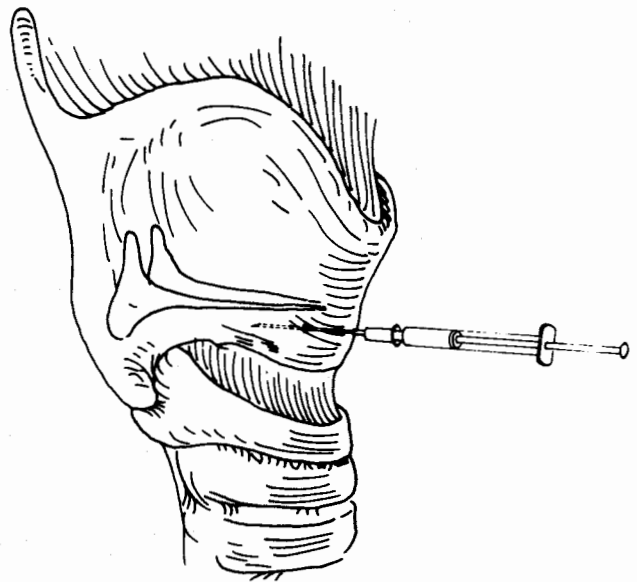


Fig. 1. Needle placement displayed in the transcartilage approach.

and low image enhancement modes were selected. This provided the necessary resolution for precise visualization of needle position and amount of collagen augmentation during placement of collagen.

After fiberoptic insertion, the patient's neck was extended when possible and the position of the cricoid and inferior border of the thyroid cartilage and thyroid notch was identified by

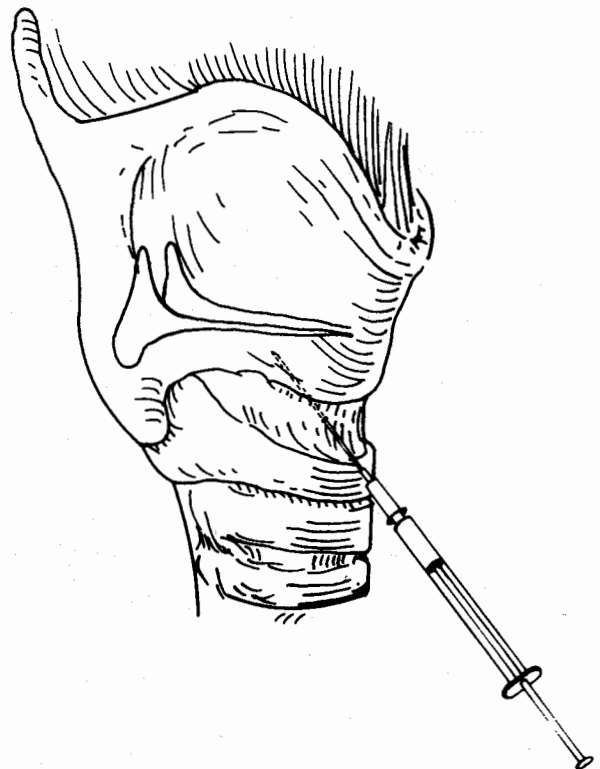


Fig. 2. Needle placement displayed in the transcricothyroid approach.

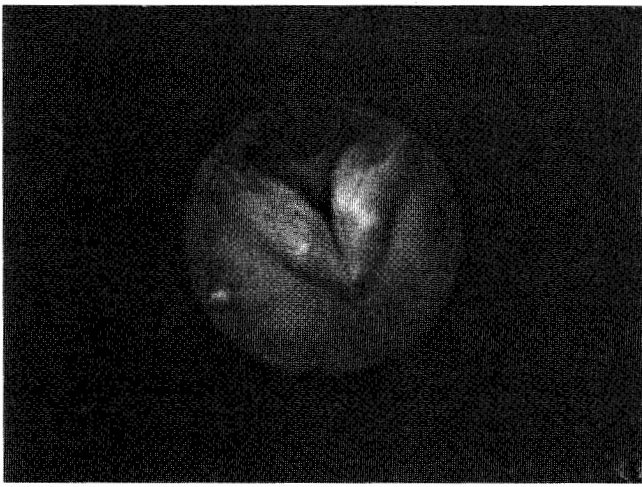

Fig. 3. Glottal configuration at rest immediately after collagen injection.

external landmarks. Because the superior surface of the vocal fold lies at approximately half the distance between the superior notch and the inferior border of the thyroid cartilage, injection was placed below this level but above the inferior thyroid cartilage margin. Transcartilaginous injection was used unless cartilage calcification prevented it, in which case needle placement was through the cricothyroid membrane (Figs. 1 and 2).

Approximately 0.25 to 0.5 mL of crosslinked collagen was typically injected in a sublamina propria plane. This provided a convex, overinjected appearance to the vocal fold, which was noted to resolve back to a straight edge in 2 to 3 days, after the expected shrinkage of the injected bolus. Injection of excess collagen into subepithelial planes was easily identified and avoided. One to 2 mL of collagen was typically required in patients whose injection was placed subglottally through the cricothyroid membrane.

After the initial injection, patients were asked to phonate and cough to disperse the collagen within the vocal fold. Additional collagen was injected until the vocal folds touched during respiration at a position midway between the anterior commissure and the vocal processes (Fig. 3). The patients were discharged home on 2 days of oral antibiotics.

Patient Survey

The patients enrolled in this study were surveyed by telephone for their experience with the collagen injection. Two had died of other medical problems before the survey and two could not be contacted. We decided to use a telephone survey for a few reasons. First, in the past we have found that this patient group generally has difficulty returning to our clinic in a timely manner, presumably because of the severity of their neurological condi-

tion. Secondly, we were interested in asking patients directly about their experience. Further, there are some reports demonstrating that perceptual measures of voice can be more sensitive than instrumental measures—listeners often hear differences that do not show up in the instrumental measures.²¹ The patients were asked to respond to the statements in Table I, using a five-point rating system ranging from “disagree strongly” (1) to “agree strongly” (5). They were also asked to estimate the effect duration of the collagen injection in weeks. Survey calls were made by a person who was familiar with the injection procedure, but was not formally affiliated with the clinic. Patients were assured that their responses were confidential and were encouraged to respond honestly. They were also asked to elaborate on their responses when appropriate.

RESULTS

Complications

No airway problems were encountered as a result of the collagen injections. Occasionally, a small amount of collagen was inadvertently injected into the glottis, but this was coughed up and expectorated readily. Needle placement into the ventricle was easily recognized. If excessive bleeding from needle puncture was observed, the procedure was terminated and attempted again on a subsequent visit. No hematomas were identified. Two patients who developed collagen nodules due to subepithelial placement underwent direct microremoval to improve their voice.

Effects on Vocal Quality

Patients enrolled in this study initially exhibited a broad spectrum of vocal dysfunction, from mild breathiness and voice fatigue to severe dysarthria and aphonia. Cognitive dysfunction was also present in some cases. Thus results of this preliminary investigation are confounded by the multitude of preinjection states.

While most patients noted improvement in their voices 2 to 3 days after injection, approximately one fifth of patients had improvement in voice and speech immediately after injection. One fifth of patients required two injections, 2 weeks apart, to obtain maximum benefit.

The following case represents an application of this procedure in a 70-year-old man with a moderately weak voice whose Parkinson disease had been diagnosed 5 years earlier. He was experiencing progressive vocal weakness, which interfered with his ability to run a large corporation. Figure 4A and B shows the laryngeal appearance before and after collagen augmentation. Figure 5A and B demonstrates the acoustic spectra before and after

TABLE I.
Patient Satisfaction Survey.

Statement	Variable of Interest
Listeners can hear me when I speak	Vocal loudness
My voice is clearer	Vocal clarity
The injection has improved my ability to socialize	Social embarrassment
The injection was easily tolerable	Tolerance of injection
Overall I am satisfied with the collagen injection	Satisfaction

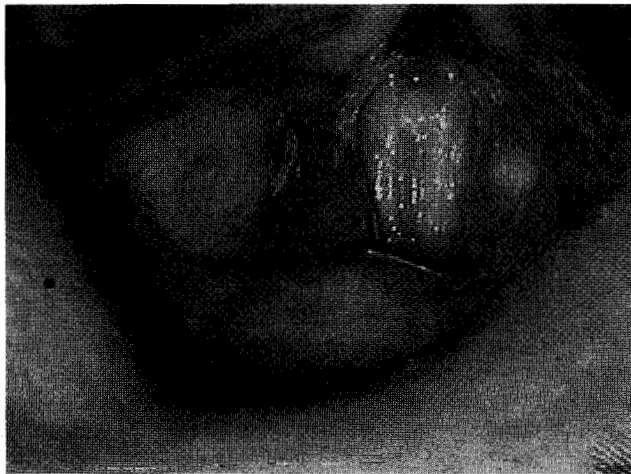
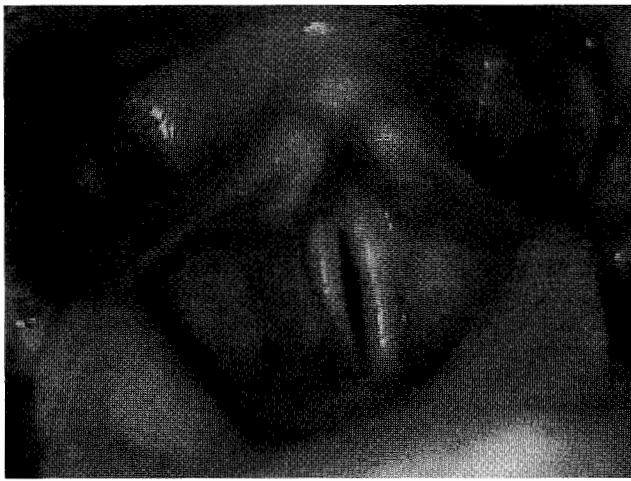


Fig. 4. **A.** Glottal configuration during the most closed segment within the phonatory cycle preinjection of a 70-year-old man. **B.** Glottal configuration during the most closed segment within the phonatory cycle after injection of the same man.

injection. Note that the collagen injection produced improved glottic closure and greater amplitude of the formants and higher harmonics.

Length of Effect

In this study augmentation with noticeable acoustic effects lasted from 4 weeks to 52 weeks (average, 12 weeks).

Patient Satisfaction

Overall, responses to the patient satisfaction survey demonstrated good levels of satisfaction with the collagen injection. The median response for the variables of vocal loudness, social embarrassment, tolerance of injection, and satisfaction was 5; the median for vocal clarity was 4. There were only a few neutral responses to the survey questions. Patients most commonly reported their happiness with the procedure, and a minority described their dissatisfaction.

Overall success of the procedure was estimated by comparing the percentage of “strongly disagree” and

“somewhat disagree” responses for the five variables with the percentage of “strongly agree” and “somewhat agree” responses. Seventy-five percent of patient responses reflected positive feelings and experiences with the procedure (i.e., strong or moderate agreement with the survey statements), compared with 16% of ratings reflecting dissatisfaction with the procedure.

Patient satisfaction appears to be related largely to the duration of treatment effects. Ratings of satisfaction were significantly correlated with patients’ estimates of treatment duration (Spearman’s rank-order correlation = 0.61).

DISCUSSION

Based on patient responses to a survey of their satisfaction with the procedure, percutaneous collagen augmentation with fiberoptic guidance is an effective means of improving vocal loudness and clarity in patients with Parkinson disease, resulting in reduced embarrassment in speaking and overall satisfaction. Objective aerodynamic and acoustic measures are also needed to validate these subjective impressions and to provide more insight into the physiological processes underlying these responses.

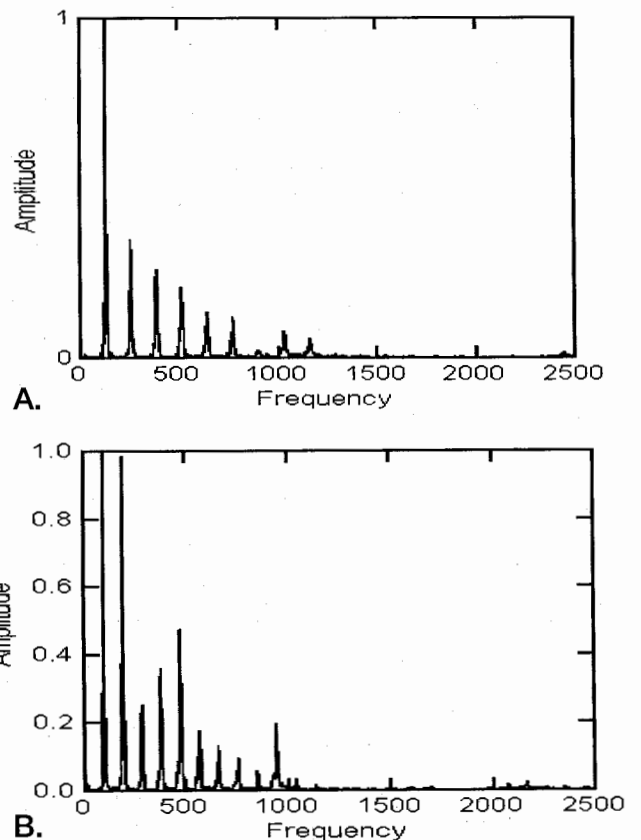


Fig. 5. **A.** Acoustic spectrum of voice during the production of the vowel /a/. Relative amplitude is displayed in arbitrary linear units. Note the relative absence of energy in the higher harmonics. **B.** Acoustic spectrum of voice during the production of the vowel /a/. Relative amplitude is displayed in arbitrary linear units. Note the relative enhancement of energy in the higher harmonics.

The duration of implant survival and sustained improvement in vocal loudness and clarity is a significant issue. The duration of voice improvement is most likely related to degree and location of initial amount of collagen injected, and rate of collagen absorption. However, the effects of these factors require future investigation. Autogenous collagen harvested from a skin paddle and fibroblast culture from a small postauricular biopsy show promise in extending augmentative effects, and further studies using these are in preparation.

Patient selection for this procedure is an additional concern. Some Parkinson patients exhibit both significant speech unintelligibility and dysphonia. Collagen injections did not improve speech intelligibility in some patients with significantly reduced articulatory precision and speech unintelligibility before injection. Consequently, these patients were often dissatisfied with the results of the procedure. On the other hand, we noted a perceptual increase in speech intelligibility in some of these patients after reduction of their dysphonia. We assume that strengthening of the voice source enhanced the other components of the speech chain. The relationship between speech unintelligibility and dysphonia before injection and success following the procedure needs further investigation.

Initially it was anticipated that patients with less severe vocal dysfunction would benefit the most from this technique. However, a number of patients who were nearly aphonic before injection regained verbal communication after injection, although they were still severely compromised. From one point of view, these patients may have benefited the most from treatment, although their postinjection voices remained less than optimal.

CONCLUSION

This simple procedure demonstrates that voice and possibly speech deficits in Parkinson disease are amenable to augmentative techniques. This procedure may be especially helpful as an adjunct to voice therapy. More importantly, these results emphasize that clinicians, medical gatekeepers, and insurance companies should realize that voice and speech defects in patients with neurodegenerative disorders are treatable. The "why bother?" attitude expressed by some when faced with patients exhibiting severe multisystem neurodegenerative diseases should be discouraged, and patients should be heartened by the knowledge that even a little improvement in one of their motor systems can make a large difference in their quality of life.

ACKNOWLEDGMENT

We would like to acknowledge the generosity of Gordon Strube, and grant # DC01797 from the NIDCD for partial funding of this research. We also want to acknowledge Joel Blumin, MD, Michael Jacobsen, MD, and Linea Peterson, MD for their help in this research. We received no funding from nor have a financial or contractual relationship with the Collagen Corporation.

BIBLIOGRAPHY

- Hartelius L, Svensson P. Speech and swallowing symptoms associated with Parkinson's disease and multiple sclerosis: a survey. *Folia Phoniatrica Logopedica* 1994;46:9-17.
- Forest K, Weismer G, Turner GS. Kinematic, acoustic, and perceptual analyses of connected speech produced by parkinsonian and normal geriatric adults. *J Acoust Soc Am* 1989;85:2608-2622.
- Darley FL, Aronson AE, Brown JR. *Motor Speech Disorders*. Philadelphia:WB Saunders Co.;1975.
- Hanson DG, Gerratt BR, Ward PH. Cinegraphic observations of laryngeal function in Parkinson's disease. *Laryngoscope* 1984;94:348-353.
- Leopold NA, Kagel MC. Laryngeal deglutition movement in Parkinson's disease. *Neurology* 1997;48:373-376.
- Baker KK, Ramig LO, Johnson AB, Freed CR. Preliminary voice and speech analysis following fetal dopamine transplants in 5 individuals with Parkinson's disease. *J Speech Lang Hear Res* 1997;40:615-626.
- Stewart C, Winfield L, Hunt A, Bressman SB, Fahn S, Blitzer A, Brin MF. Speech dysfunction in early Parkinson's disease. *Mov Disord* 1995;10:562-565.
- Hariz MI, De Salles AA. The side-effects and complications of posteroventral pallidotomy. *Acta Neurochirurg Suppl* 1997;68:42.
- Ramig LO, Countryman S, Thompson LL, Horii Y. Comparison of two forms of intensive speech treatment for Parkinson disease. *J Speech Hearing Res* 1995;38:1232-1251.
- Ramig LO, Dromey C. Aerodynamic mechanisms underlying treatment-related changes in vocal intensity in patients with Parkinson disease. *J Speech Hearing Res* 1996;39:798-807.
- Perez KS, Ramig LO, Smith ME, Dromey C. The Parkinson larynx: tremor and videostroboscopic findings. *J Voice* 1996;10:354-361.
- Green DC, Ward PH, Berke GS, Gerratt BR. Point-touch technique of botulinum toxin injection for the treatment of spasmodic dysphonia. *Ann Otol Rhinol Laryngol* 1992;101:883-887.
- Ford CN, Bless DM. Clinical experience with injectable Collagen for vocal fold augmentation. *Laryngoscope* 1986;96:863-869.
- Ford CN, Martin DW, Warner TF. Injectable collagen in laryngeal rehabilitation. *Laryngoscope* 1984;513-518.
- Remacle M, Marbaix E, Bertrand B, Hamoir M, van den Eeckhaut J. Correction of glottic insufficiency by collagen injection. *Ann Otol Rhinol Laryngol* 1990;99:438-444.
- Trapp T, Berke GS, Bell T, Hanson DG, Ward PH. Effect of vocal fold augmentation on laryngeal vibration in simulated recurrent laryngeal nerve paralysis: a study of Teflon and Phonogel. *Ann Otolaryngol* 98:220-227
- Ford CN, Gilchrist KW, Bartell TE. Persistence of injectable collagen in the human larynx: a histopathologic study. *Laryngoscope*; 1987;97:724-727.
- Remacle M, Marbaix E, Hamoir M, Declaye X, van den Eeckhaut J. Initial long-term results of collagen injection for vocal and laryngeal rehabilitation. *Arch Otorhinolaryngol* 1989;246:403-406.
- Smitheran J, Hixon TJ. A clinical method for estimating laryngeal airway resistance during vowel production. *J Speech Hearing Disord* 1981;46:138-146.
- Stathopoulos ET, Sapienza CM. Respiratory and laryngeal function of women and men during vocal intensity variation. *J Speech Hearing Res* 1993;36:64-75.
- Descler DG, Doherty ET, Reed CG, Singer MI. Quantitative and qualitative analysis of tracheoesophageal voice after pectoralis major flap reconstruction of the neopharynx. *Otolaryngol Head Neck Surg* 1988;118:771-776.